

Arthroplasty for Femoral Neck Fractures

Why I Use the Anterior Approach

Philip J. Kregor, MD,* Jeffery W. Mast, MD,† and Kurtis S. Staples, MD‡

Summary: TO COME. **Key Words:** TO COME.

INTRODUCTION

Femoral neck fractures in elderly patients are a common problem for the orthopaedic surgeon and are projected to grow in number. It is estimated that there will be 1/2 million femoral neck fractures treated per year by 2050.^{1,2} Challenges in the treatment of the elderly patient with a femoral neck fracture include medical comorbidities, fragility of the patient, osteoporosis, and rehabilitation issues. In general, a physiological cut off of 65 has been used to differentiate between internal fixation and arthroplasty in the treatment of femoral neck fractures. This controversy has been nicely explored by Dijkman et al in this issue.³ In the setting of a displaced femoral neck fracture in the elderly patient treated with arthroplasty, several problems remain. There is concern regarding infection, dislocation (especially with a total hip arthroplasty), leg length inequality, and adductor dysfunction. Bhandari et al has nicely summed up the concerns regarding arthroplasty (when compared with open reduction internal fixation) in the elderly patient with a displaced femoral neck fracture.⁴ It was stated, "... for every 100 patients treated with arthroplasty instead of internal fixation, 17 revision surgeries can be avoided, but at the expense of 4 more wound infections, 4 additional deaths, and 1 hip dislocation."⁴ There is also increasing evidence that total hip

arthroplasty (as opposed to hemiarthroplasty) leads to better long-term function, especially in the "younger" patient.^{5,6}

Matta et al describe the "single-incision anterior approach for total hip arthroplasty on an orthopaedic table" in treatment of degenerative arthritis in 437 primary total hip arthroplasties.⁷ They reported a 0.61% dislocation rate and a leg length difference averaging 3 ± 2 mm. As described by Matta et al, the advantages of an anterior approach for hip arthroplasty utilizing the Heuter modified Smith-Peterson approach include:

- supine position,
- small incision (9 to 12 cm),
- no muscle detachment from the hip,
- preservation of the "hip deltoid" of the obturator internus, obturator externus, and piriformis, as well as the posterior hip capsule,
- improved control of component position in leg length as intraoperative fluoroscopy is able to be used during the surgical procedure,
- low risk of dislocation and no need for posterior hip flexion precautions,
- rapid and easy postoperative mobilization of the patient, because there is no devitalization of the abductors with the approach.

It is a natural extension of these results and an advantage of an anterior total hip arthroplasty for degenerative arthritis to use this approach in the geriatric patient with an osteoporotic femoral neck fracture. The premise is that the advantage of an anterior approach may be even more relevant in a debilitated low reserve, frail patient with a femoral neck fracture. Why would this be the case? The potential advantages of decreased dislocation, early return to function, accurate restoration of leg length

From the *Division of Orthopaedic Trauma, Vanderbilt Orthopaedic Institute, Nashville, Tennessee; †Ortho Trauma and Hip Surgery, Vanderbilt Orthopaedic Institute, Nashville, Tennessee; and ‡The Core Institute, Sun City West, Arizona.

Address correspondence and reprint requests to Philip J. Kregor, MD, Associate Professor and Director, Division of Orthopaedic Trauma, Vanderbilt Orthopaedic Institute, Nashville, TN. E-mail: philip.kregor@vanderbilt.edu

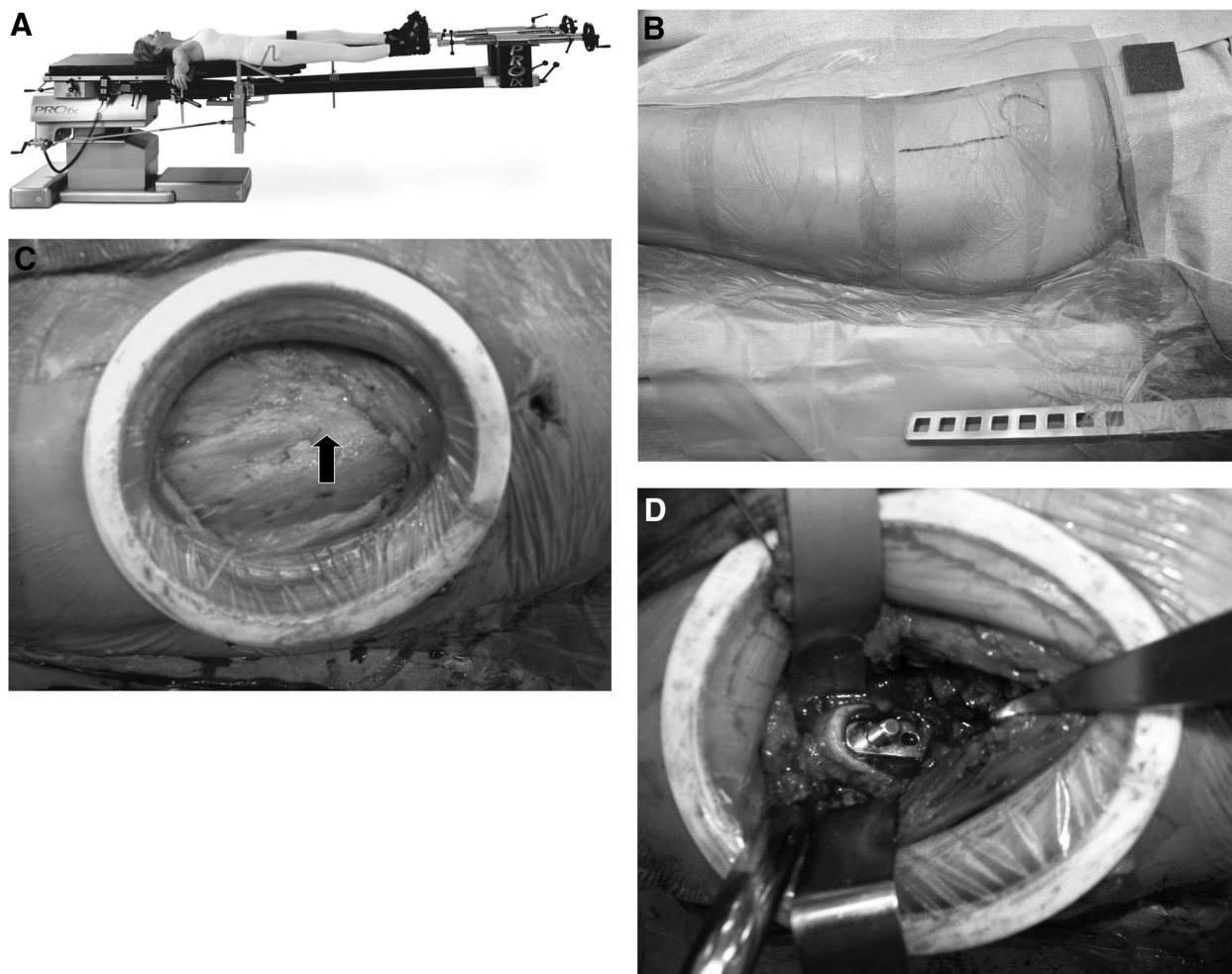


FIGURE 1. **A**, The patient is placed supine on the OSI (MIZUHO OSI, Union City, CA) PROFX table (or HANNA table). Notice the leg spars, which allow for manipulation of the leg, and the table hook apparatus, which helps facilitate exposure of the proximal femur. **B**, The ASIS is outlined. The 10-cm incision begins approximately 1 cm distal and 1 cm lateral to the anterior superior iliac spine. It is centered over the tensor fascia muscle belly. **C**, The interval between the tensor fascia muscle belly and the sartorius is delineated by a fatty stripe. This is shown by the arrow in this figure panel. The sheath over the tensor fascia muscle belly is incised to gain access to the anterior hip capsule. **D**, After appropriate exposure of the proximal femur, the broaching and insertion of the femoral component can be placed under direct visualization.

and offset, and supine positioning (especially in unstable patient) may be even more advantageous in this patient population. It may be used for either hemiarthroplasty or total hip arthroplasty.

At the Orthopaedic Trauma Association in 2008, the authors reported on the initial retrospective series of 56 arthroplasties (33 total hip arthroplasties and 23 bipolar arthroplasties) treated by a single surgeon for all displaced femoral neck fractures in patients 65 years of age and older.⁸ In this series, no hip flexion precautions were used and immediate weightbearing was carried out. There were no infections or dislocations. The implant positioning demonstrated an average leg length differential of 1.1 mm for those cases with total hip arthroplasty

and 1.4 mm for those patients with bipolar arthroplasty. For the cases with a total hip arthroplasty, acetabular cup abduction averaged 39 degrees.

SURGICAL TECHNIQUE

The patient is brought into the operating room and has appropriate anesthesia (general or spinal) administered. Prophylactic antibiotics include gram-positive coverage (cefazolin or vancomycin). Gram-negative coverage is included (generally Levaquin) in those cases in which a urinary tract infection is confirmed or suspected. The surgical technique relies on the use of an OSI ProFX or Hanna table (Fig. 1A). The patient is transferred to the

F1

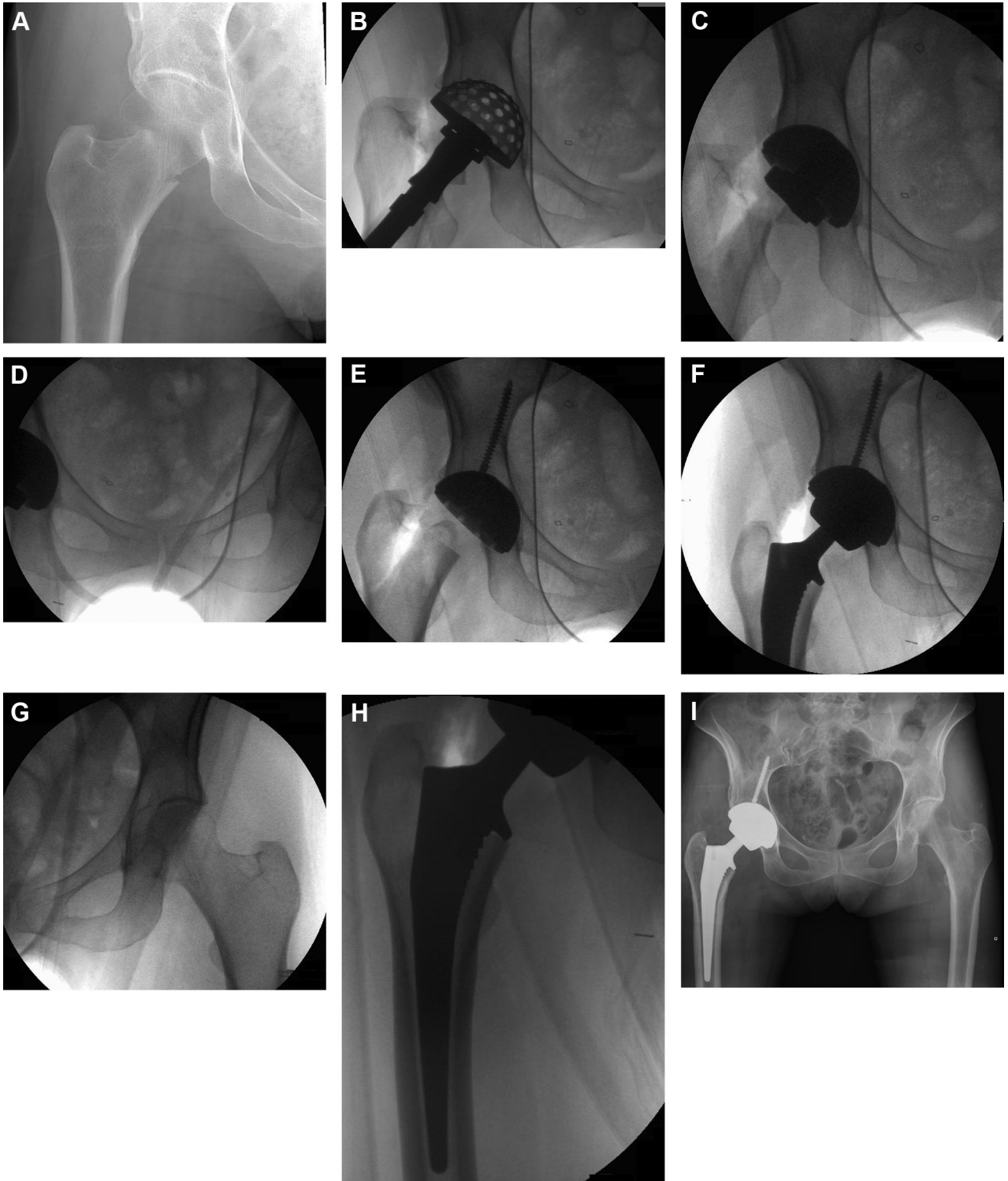


FIGURE 2. Case example of a 62-year-old female with moderate osteoporosis who sustained a right femoral neck fracture and a low energy fall. She has a type I diabetes mellitus. A, Anteroposterior (AP) hip radiograph demonstrating a displaced femoral neck fracture. After careful consideration and discussion with the patient and family, and taking into account her high functional activity, it was elected to perform a right total hip arthroplasty (as opposed to a hemiarthroplasty). B, Intraoperative x-ray demonstrating visualization of the reaming process. While this does not need to be done under fluoroscopic visualization, it is possible. C, Direct visualization of the cup placement. D, It is important for the surgeon to ensure that a proper

surgical table in the supine position. Both feet are placed into the boots that accompany the table. The arms are placed at arm boards at an angle of approximately 80 degrees from the axilla. A Foley catheter has been placed and is secured. The entirety of the left hip area and lower extremity is then prepared and draped out.

The surgical incision is that of a Heuter approach, which has been nicely described by Matta et al (Fig. 1B). The incision is intended to be over the tensor fasciae muscle belly. It begins approximately 1 cm distal and 1 cm lateral to the ASIS and is obliquely directed toward the lateral aspect of the distal femur. The skin and subcutaneous tissue is divided sharply down to the level of the tensor fasciae sheath. A common mistake at this point would be to be medial to the ASIS and enter the sheath of the sartorius rather than the tensor fasciae. The tensor fascia sheath is incised for the length of the skin incision and scissors are used to extend the release of the tensor fascia sheath distally for approximately 3 to 4 cm (Fig. 1C). By staying in the tensor fascia sheath, and not being medial, the surgeon avoids the major branch of the lateral femoral cutaneous nerve of the thigh. Blunt finger dissection is then used to delineate the interval between the tensor fascia muscle belly and the superolateral hip capsule. A Cobra retractor is then placed along the superolateral aspect of the hip capsule. Retraction of the tensor fasciae muscle belly laterally then exposes the lateral circumflex vessels, which are accompanied by surrounding adipose tissue. The vessels are identified and electrocauterized or ligated with suture. Having done this, an elevator is then used to undermine the rectus femoris off of the anterior hip capsule and a Cobra retractor may then be placed on the inferomedial aspect of the hip capsule. An L-shaped capsulotomy is then made with the vertical limb on the superior aspect of the femoral neck and the transverse limb (inferior limb) along the intertrochanteric line. A suture is then placed at the corner of this capsulotomy flap and the capsule can be closed at the end of the surgical procedure. The Cobra retractors are then placed along the superior and inferior aspect of the femoral neck inside the hip capsule. At this point the femoral neck is exposed. A femoral neck cut can then be made at the appropriate level. This level can be determined by preoperative templating. A small amount of traction is then applied to the lower extremity, which

distracts not only the femoral neck cut surfaces but also the femoral neck fracture area. This then exposes an intercalary fragment with the lower end of the fragment being at the femoral neck cut and the upper end of the fragment being at the femoral neck fracture. This intercalary segment can then be removed with the use of a rongeur. A corkscrew can then be used to remove the femoral head fragment. The medial capsular attachment onto the femoral neck is removed with the leg in approximately 50 to 60 degrees of external rotation. At this point, the lesser trochanter can be easily visualized by placement of a small Hohman retractor on the inferior edge of the lesser trochanter.

Acetabular exposure is aided by approximately 40 degrees of external rotation of the lower extremity and 1 or 2 turns of traction on the lower extremity (Fig. 1D). A specially designed retractor on the inferomedial aspect of the acetabulum aids in this exposure. An additional retractor on the anterior wall is helpful to expose the acetabulum. However, caution must be used with any spiked retractor in the setting of osteoporotic bone so as to not create a defect in the anterior wall. (An alternative is to lift up on the suture of the anterior hip capsule and/or use a right-angle retractor to retract the sartorius muscle belly. The acetabulum can be examined, and reaming and cup insertion can be performed under fluoroscopic guidance if desired. It is imperative that the surgeon ensures that a good anteroposterior pelvis radiograph is being obtained with the fluoroscopy machine. This requires small adjustments in the leveling of the operating room table and may require small adjustments in the fluoroscopy machine in terms of the patient's lordosis.

After the acetabular cup and liner have been placed, the femoral component may be placed. The exposure of the proximal femur is aided by external rotation of approximately 90 to 100 degrees of the lower extremity, extension of the lower extremity of 30 to 50 degrees, and adduction of the lower extremity by approximately 20 to 30 degrees. A specially-designed table hook for the OSI ProFX or Hanna table can be placed just proximal to the lesser trochanter for elevation of the proximal femur into the surgical wound. At this point, the lateral capsular attachment onto the femoral neck is removed and a rongeur is used to remove the lateral femoral neck. If an uncemented femoral component is to be placed, broaching is then carried out. (Although cemented femoral

FIGURE 2. (cont.). AP pelvic radiograph is obtained to accurately judge a cup positioning. Small changes in the tilt of the table can be made to facilitate this. **E**, An advantage of the anterior approach is precise visualization and knowledge of acetabular cup placement and screw placement. **F**, Intraoperative fluoroscopic view of the right hip total hip arthroplasty. This can be compared with the opposite hip. **G**, An identical radiograph of the left hip can be compared in terms of leg length and offset to the right hip. **H**, Intraoperative fluoroscopic visualization of appropriate placement of the femoral stem. **I**, Postoperative AP pelvis radiograph demonstrating appropriate right total hip arthroplasty. This was accomplished through a 10-cm surgical incision. The patient required a walker for 5 days postoperatively and a cane for 4 days after that. The patient did not require narcotics 3 days after the total hip arthroplasty.

components may be used with this technique, the author strongly prefers a hydroxyapatite coated impaction femoral stem [DePuy Corail femoral stem, DepuyOrthopaedics, Inc., Warsaw, IN], which has been advantageous even in capacious osteoporotic femoral canals.) With the femoral broach in position, the trial components may be examined fluoroscopically to look for leg length, femoral component positioning, and offset. A useful technique described by Joel Matta, MD is to print out a fluoroscopic view of the involved hip and overlay this with the printout from the opposite hip. Small adjustments in leg length or offset can be made at this point by adjusting neck length and/or offset of the femoral component. After this has been investigated, the hip is dislocated. This is done with a simultaneous motion of traction, external rotation, and adduction of the hip utilizing the leg spar of the Hanna or OSI ProFX table. It may be also aided by the use of a dislocation hook around the femoral neck. As with any total hip arthroplasty, sufficient traction must be placed before a rotatory force is placed on the lower extremity to avoid any potential femoral shaft fracture. With the proximal femur now exposed, the real components may be impacted into position. If there is any discrepancy between where the femoral component has been inserted compared with the previous broach, the trial femoral head and neck may be performed.

Fluoroscopy may be used as a final confirmation of final implant positioning. The wounds are copiously irrigated. A drain may be placed in the inner capsular region if desired by the surgeon. The capsule is loosely closed utilizing absorbable suture. The fascia overlying the tensor fasciae muscle belly is then closed utilizing a running absorbable suture. The subcutaneous tissues are closed utilizing absorbable suture, the skin is closed utilizing a running subcuticular suture, and a skin sealant is then applied. The advantage of such a skin sealant (eg, Dermabond) is that it allows patients to immediately shower and seals the wound from urinary or fecal contaminate in the rehabilitation of the patient.

If a hemiarthroplasty is desired, the labrum and acetabulum are left untouched and the femoral component can be placed in the identical manner as described above.

CONCLUSIONS

The disadvantages of an anterior approach hip arthroplasty for treatment of a femoral neck fracture in a geriatric patient include the necessity for the surgeon to learn a new surgical approach and technique, as well as the need for a specially-designed orthopaedic table for this technique. In my experience, however, the advantages of this technique have been impressive. Most notably, as the patient has no devitalization of the abductors, their mobilization postoperatively is impressive. The surgeon can comfortably perform a total hip arthroplasty (if desired) without the fear of dislocation. There is no need for hip flexion precautions or avoidance of weightbearing. Finally, the ability to have a "real time" view of implant position provides the surgeon with added confidence in the postoperative radiographic result. Randomized trials comparing the anterior approach with more traditional approaches in this patient population will be needed to delineate any advantages or disadvantages.

REFERENCES

1. Cummings SR, Rubin SM, Black D. The future of hip fractures in the United States. Numbers, costs, and potential effects of postmenopausal estrogen. *Clin Orthop Relat Res.* 1990;252:163-166.
2. Schneider EL, Guralnik JM. The aging of America. Impact on health care costs. *JAMA.* 1990;263:2335-2340.
3. Dijkman B, Kooistra B, Ferguson T, et al. Decision making: ORIF versus arthroplasty for femoral neck fractures. *Tech Orthop.* 2008; 23:xx-xx.
4. Bhandari M, Devereaux PJ, Swiontkowski MF, et al. Internal fixation compared with arthroplasty for displaced fractures of the femoral neck. A meta-analysis. *J Bone Joint Surg Am.* 2003;85-A: 1673-1681.
5. Keating JF, Grant A, Masson M, et al. Randomized comparison of reduction and fixation, bipolar hemiarthroplasty, and total hip arthroplasty: treatment of displaced intracapsular hip fractures in healthy older patients. *J Bone Joint Surg Am.* 2006;88:249-260.
6. Blomfeldt R, Törnkvist H, Ponzer S, et al. Comparison of internal fixation with total hip replacement for displaced femoral neck fractures. Randomized, controlled trial performed at four years. *J Bone Joint Surg Am.* 2005;87:1680-1688.
7. Matta JM, Shahrardar C, Ferguson T. Single-incision anterior approach for total hip arthroplasty on an orthopaedic table. *Clin Orthop Relat Res.* 2005;441:115-124.
8. Staples K, Kregor PJ. Anterior hip arthroplasty for treatment of acute displaced elderly femoral neck fractures. Presented at the Orthopedic Trauma Association annual meeting, 2008, Denver, CO.

AUTHOR QUERIES

AUTHOR PLEASE ANSWER ALL QUERIES

1

AQ1— Please provide a one paragraph summary and key words to accompany this article.

AQ2— Reference for Dijkman has been added and other references have been renumbered.

AQ3— Figure callouts are not allowed in headings. Please indicate where Figure 2 should be called out in text.

AQ4— Please provide a reference for the technique by Joel Matta.

AQ5— Please include complete address for “correspondence including street name and zip code.